

Prevalence of Non-glaucomatous Optic Atrophy in Ehime Mbanjo, Nigeria

G. C. Ihesiulor^{1*}, J. N. Chimchetam¹, U. A. Udo¹, C. O. Ahuama¹, C. O. Timothy¹,
Omaka, Uma Andrew¹ and O. G. Ihesiulor¹

¹Department of Optometry, Abia State University, Uturu, Nigeria.

Authors' contributions

This work was carried out in collaboration among all authors. Authors JNC and GCI designed the study, performed the statistical analysis, wrote the protocol and wrote the first draft of the manuscript. Authors JNC and GCI managed the analyses of the study. Author JNC managed the literature searches. All authors read and approved the final manuscript.

Article Information

Editor(s):

(1) Dr. Seydi Okumus, Assistant Professor, Gaziantep University, Tip Fakultesi, Goz Hastaliklari Anabilim Dalı, Gaziantep, Turkey.

Reviewers:

(1) Engy M. Mostafa, Sohag University, Egypt.
(2) Syed Shoeb Ahmad, Ibn Sina Academy of Medieval Medicine and Sciences, India.
(3) Umezurike Benedict Chidozie, Nigeria.

Complete Peer review History: <http://www.sdiarticle4.com/review-history/53868>

Original Research Article

Received 28 October 2019

Accepted 03 January 2020

Published 20 January 2020

ABSTRACT

Purpose: this population-based epidemiological study highlights the prevalence and causes of non-glaucomatous optic atrophy (NGOA) in Ehime Mbanjo.

Methods: In this prospective study, the case history, visual acuity, pupillary reflex and funduscopy examination for three hundred and forty-nine (349) subjects between ages 17-85 was carried out using a pro forma, snellen chart, pen light and ophthalmoscope respectively. The presumed NGOA subjects (45) were further examined with perimetry and tonometry to rule out glaucomatous OA. The data collected was analyzed with the use of ANOVA and Chi-square statistical tests.

Results: The highest prevalence rate (20%) was accounted for by retinitis pigmentosa, nutritional amblyopia and unknown causes. Females (53.3%) more than males, had NGOA. Age ranges 57≤77 had (20%) highest prevalence of NGOA. Most of the presumed NGOA cases (34.6%) had visual acuity of < 6/6-6/18 (20/20 – 20/63).

Conclusion: The total prevalence of NGOA in Ehime Mbanjo is 13.0%. The prevalence of NGOA is related to causes and visual acuity but not dependent on sex and age. More studies with larger

*Corresponding author: E-mail: chikezieihesiulor@yahoo.co.uk;

sample sizes are however warranted to strengthen the correlation. Patients with presumed OA should be thoroughly evaluated as it may be a treatable condition or presentation of some other life-threatening conditions.

Keywords: Optic atrophy; glaucoma; prevalence.

1. INTRODUCTION

Optic atrophy is not a diagnosis but simply an ophthalmoscopic sign similar to finding upper extremity weakness; the cause of the weakness will still be determined [1]. Non-glaucomatous optic atrophy (NGOA) occurs when the disc is thought to be less pink or paler than normal in absence of characteristic glaucomatous field defects/ optic disc changes [2]. A wide range of normal optic disc exist thus, it can be difficult to be sure if optic atrophy is present. A normal optic disc is often pinker on the nasal side, with relative temporal pallor [3]. The central cup of the disc appears pale because the white lamina cribrosa is visible. Optic disc in patients with axial myopia may appear paler. Furthermore, media opacities such as cataract can impart more color to the disc, and pseudophakia can result in a paler disc appearance. Thus, optic disc pallor should not be use synonymously with optic atrophy. It is essential to compare an individual's optic discs, because they will usually have the same color. If true optic atrophy exists, it should be accompanied by visual loss (acuity and/or peripheral vision), decreased color perception (if acuity is compromised) and relative afferent papillary defect unless the damage is symmetric [2,3]. However, visual field is a mostly affected in optic neuropathy [4].

Optic atrophy is the late stage changes that takes place in optic nerve resulting from axonal degeneration in the pathway between the retina and the lateral geniculate body, manifesting with disturbance in visual function and in the appearance of the optic nerve head [5]. Degeneration of nerve fiber is associated with attempt but unsuccessful regeneration which is characterized by proliferation of astrocytes and glial tissue. Ophthalmoscopic appearance of the atrophic optic disc depends upon the disturbance between loss of nerve tissue and gliosis [6]. Non-glaucomatous optic atrophy is any optic atrophy that proceeds from optic neuropathy other than glaucoma. Example traumatic optic neuropathy, ischemic optic neuropathy, toxic/nutritional optic neuropathy et cetera [6].

Worldwide the principal cause of optic neuropathy is glaucoma but the following are the

main differential signs in a fundus examination between glaucomatous damage of optic nerve head and NGOA. In glaucomatous eyes the neuro-retinal ring appears to have a good healthy color but markedly thin; usually at the superior and inferior, showing a focal enlargement of the cup. Other characteristic signs are asymmetry of the cupping between the two eyes, peripapillary atrophy and disc hemorrhages without swelling. The principal fundoscopic signs in NGOA are the neuro-retinal ring's pallor, especially in temporal (showing a horizontal enlargement of the cup) or an optic nerve head is swelling (if anterior portion is affected) in the acute phase. Therefore, acquired enlargement of the cup does not always suggest glaucoma [5,6]. Arteritic anterior ischemic optic neuropathy seen in giant cell arteritis (GCA-AAION) cause an enlargement of the cup in most of patients affected [7]. As glaucoma is a bilateral disease, the patients do not usually present a relative afferent pupillary defect (RAPD). There is no proven treatment that reverses optic atrophy. However, treatment that is initiated before the development of optic atrophy can be helpful in saving useful vision. Early diagnosis and prompt treatment can help patients with compressive and toxic neuropathies [4].

Optic neuropathy is a significant cause of visual impairment among Nigerians [8]. A study in low vision clinic in Ibadan showed that the third commonest condition among 193 patients attending over a 3-year period was optic atrophy [9]. Retinitis pigmentosa (16%) and albinism (13.2 percent) especially, among children, were the commonest conditions associated with optic atrophy in these cases [9]. Compressive optic neuropathy is a preventable and treatable cause of optic atrophy in a retrospective review of 100 randomly selected cases. Etiology of optic atrophy could not be identified in 62% of patients, on the review in question [10]. On the other hand, in Port Harcourt in a review of 99 patients with non-glaucomatous optic neuropathy, 40% of the patients had optic atrophy. Majority of the patients in the Port Harcourt study were presumed to have nutritional amblyopia (31.1%) or demyelinating optic neuritis (27.3%) although 41.4% were undiagnosed [11]. The prospective study aims at determining the cause and

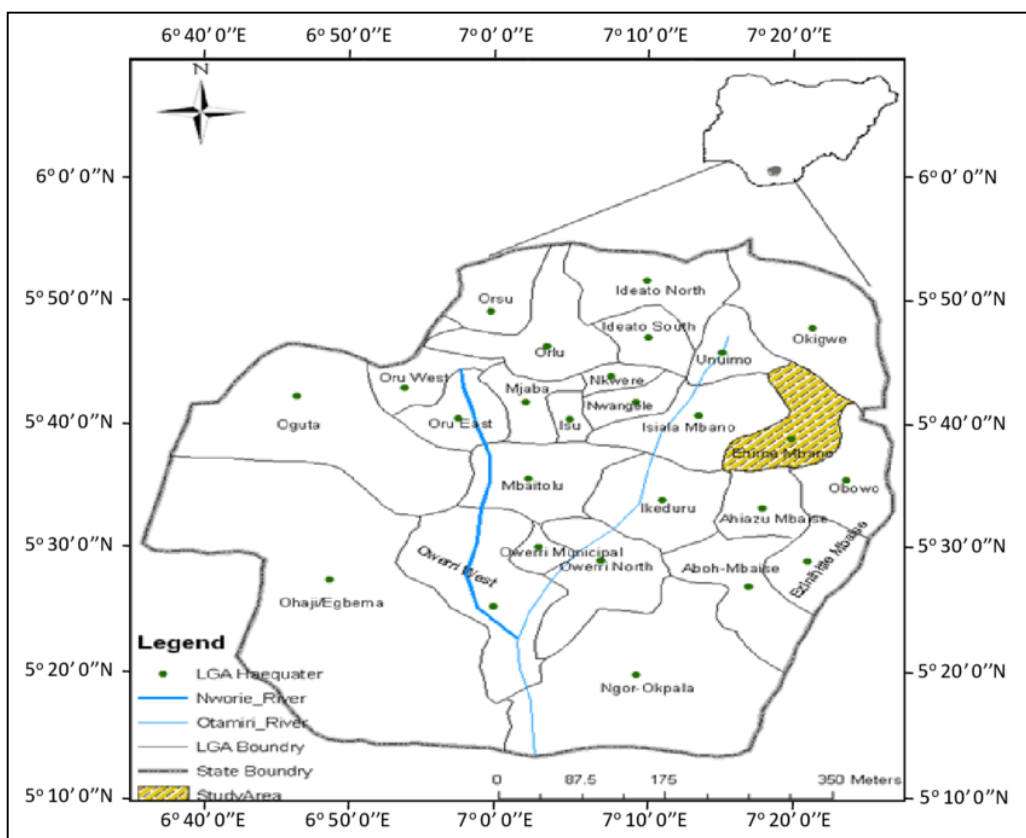


Fig. 1. Map of Ehime Mbano, Imo State, South Eastern Nigeria adapted from [12]

prevalence of non-glaucomatous optic atrophy in Ehime Mbano, in Nigeria. Also, the age, sex and visual acuity of participants with presumed NGOA.

2. METHODS

2.1 Sampling Procedure

An outreach was carried out in the Ehime Mbano which involved the following procedures: case history, visual acuity (both far and near), swinging flash light test, ophthalmoscopy, visual field test and tonometry. The subjects presented with optic atrophy. Subjects that presented with glaucomatous optic atrophy were excluded. Subjects were between 17 to 85 years of age.

2.2 Data Collection

Snellen's visual acuity (standard directional "E" chart and literate chart) both far and near. Pen torch for swinging flash light test to evaluate RAPD (relative afferent pupillary defect), Ophthalmoscope (Keeler) and 0.5% tropicamide

eye drop for dilated funduscopy. Fluorescein strips and Perkin's tonometer for intraocular pressure measurement. Tangent screen (Bjerrum's screen), Black wand and 1.5 mm target for visual field test.

Out of three hundred and fifty-seven (357) subjects that attended the exercise, three hundred and forty-nine (349) were within the age range of 17 to 85 years and this constituted the study population. Out of three hundred and forty-nine (349) subjects, one hundred and thirty-seven (137) were females and two hundred and fourteen (212) were males.

Name, age, sex, occupation, address and chief complaint of each patient was obtained, either from the patient or through his/her guardian which laid foundation to the diagnosis of optic atrophy as some presented with associated symptoms.

Ocular and medical history was properly taken as this helped in determining the cause of optic atrophy. The following four major questions were asked to subjects that presented with vision loss;

- Q1: Is the vision loss unilateral or bilateral?
- Q2: Was the vision loss progressive or acute?
- Q3: Is the vision loss still decreasing, stable or improving?
- Q4: What is the past medical history and family history?

2.3 Statistical Analysis

ANOVA was used to analyze the prevalence of presumed non-glaucomatous optic atrophy according to age and chi-square was used to analyze sex, causes and visual acuity of subjects with non-glaucomatous optic atrophy. The data was analyzed and interpreted to suit the objectives of the study. Analysis of the data was done to establish the prevalence of non-glaucomatous optic atrophy in Ehime Mbanjo.

3. RESULTS

Table 1 shows distribution of subjects screened during the exercise. Out of the three hundred and forty nine (349) subjects screened, 51 (14.6)% reside in Ehime, 26 (7.4)% in Umualumaku, 47 (13.5)% in Umurumo, 51 (14.6)% in Umuezeala, 20 (5.7)% in Nzerem, 31 (8.9)% in Ikpe Nsu, 21 (6.0)% in Ihite Nsu, 27 (7.7)% in Umuezeala Nsu, 38 (10.9)% in Umueze 1 and 42 (12.0)% reside in Umukabia.

Table 2 shows prevalence of non-glaucomatous optic atrophy according to sex. Prevalence of

non-glaucomatous optic atrophy in males is 21 (46.7)%, 24 (53.3)% in females and the total prevalence of non-glaucomatous optic atrophy is 45 (13.0)%.

Table 3 shows prevalence of non-glaucomatous optic atrophy according to age; Out of 45 (100)% subjects diagnosed of non-glaucomatous optic atrophy, 2 (4.4)% were between 17-<27, 8 (17.8)% were between 27-<37, 5 (11.1)% were between 37-<47, 7 (15.6)% were between 47-<57, 9 (20)% were between 57-<67, 9 (20)% were between 67-<77 and 5 (11.1)% were between 77-<87.

Table 4 shows prevalence of non-glaucomatous optic atrophy according to causes. Optic atrophy was caused by RP in 9 (20)% subjects, chorioretinitis in 5 (11.1)% subjects, AAION in 2 (4.4)% subjects, moderate chronic papilloedema in 5 (11.1)% subjects, nutritional amblyopia in 9 (20)% subjects, trauma in 6 (13.3)% subjects and the cause was unknown in 9 (20)%.

Table 5 shows distribution of visual acuity on number of eyes with non-glaucomatous optic atrophy; Visual acuity of <6/6-6/18 was present in 28 (34.6)% eyes, visual acuity of <6/18-6/60 was present in 20 (24.7) eyes, visual acuity of <6/60-3/60 was present in 10 (12.3)% eyes, visual acuity of <3/60-1/60 was present in 8 (9.9)% eyes, visual acuity of CF-LP was present in 10 (12.3)% eyes and 5 (6.2)% eyes presented with NLP.

Table 1. Distribution of subjects screened during the exercise in ten communities visited out of twenty-nine communities

Communities visited	Number of females	Number of males	Total number of subjects
Ehime	30 (14.2)%	21 (15.3)%	51 (14.6)%
Umualumaku	15 (7.1)%	11 (8.0)%	26 (7.4)%
Umurumo	34 (16.0)%	13 (9.5)%	47 (13.5)%
Umuezeala	28 (13.2)%	23 (16.8)%	51 (14.6)%
Nzerem	12 (5.7)%	8 (5.8)%	20 (5.7)%
Ikpe Nsu	17 (8.0)%	14 (10.2)%	31 (8.9)%
Ihite Nsu	14 (6.6)%	7 (5.1)%	21 (6.0)%
Umuezeala Nsu	17 (8.0)%	10 (7.3)%	27 (7.7)%
Umueze 1	20 (9.4)%	18 (13.1)%	38 (10.9)%
Umukabia	25 (11.8)%	12 (8.8)%	42 (12.0)%
Total	212 (60.7)%	137 (39.3)%	349 (100)%

Table 2. Prevalence of non-glaucomatous optic atrophy (NGOA) according to sex

Sex	Population of subjects (%)	Number of subjects with NGOA (%)
Males	212 (60.7)%	21 (46.7)%
Females	137 (39.3)%	24 (53.3)%
Total	349	45 (13.0)%

Table 3. Prevalence of non-glaucomatous optic atrophy (NGOA) according to age and sex

Age	Number of males with NGOA (%)	Number of females with NGOA (%)	Total number of subjects with NGOA (%)
17-<27	0	2 (8.3)%	2 (4.4)%
27-<37	1 (4.8)%	7 (29.2)%	8(17.8)%
37-<47	4 (19.0)%	1 (4.2)%	5 (11.1)%
47-<57	5 (23.8)%	2 (8.3)%	7 (15.6)%
57-<67	2 (9.5)%	7 (29.2)%	9 (20)%
67-<77	7 (33.3)%	2 (8.3)%	9 (20)%
77-<87	2 (9.5)%	3 (12.5)%	5 (11.1)%
Total	21 (41.7)%	24 (58.3)%	45 (100)%

Table 4. Prevalence of non-glaucomatous optic atrophy according to causes

Causes	Number of males (%)	Number of females (%)	Total number of subjects (%)
RP	2 (9.5)%	7 (29.1)%	9 (20)%
Chorioretinitis	4 (19.0)	1 (4.2)%	5 (11.1)%
AAION	1 (4.8)%	1 (4.2)%	2 (4.4)%
Papilloedema	3 (14.3)%	2 (8.3)%	5 (11.1)%
Nutritional Ambyopia	3 (14.3)%	6 (25.0)%	9 (20)%
Unknown	4 (19.0)%	5 (20.8)%	9 (20)%
Total	21 (46.7)%	24 (53.3)%	45 (100)%

RP: Retinitis Pigmentosa, AAION: Anterior Arteritic Optic Neuropathy

Table 5. Distribution of visual acuity on number of eyes with non-glaucomatous optic atrophy

Visual acuity	Right eye	Left eyes	Total number of eyes
<6/6-6/18	15 (37.5)%	13 (31.7)%	28 (34.6)%
<6/18-6/60	8 (20)%	12 (29.3)%	20 (24.7)%
<6/60-3/60	4 (10)%	6 (14.6)%	10 (12.3)%
<3/60-1/60	5 (12.5)%	3 (7.3)%	8 (9.9)%
CF-LP	5 (12.5)%	5 (12.2)%	10 (12.3)%
NLP	3 (7.5)%	2 (4.9)%	5 (6.2)%
Total	40	41	81

CF: Counting Finger, LP: Light Perception, NLP: No Light Perception

Table 6. ANOVA for research hypothesis two

	Sum of squares	Df	Mean square	F-ratio	F-tab
Between Groups	19.9	6	3.23	0.426	3.87
Within Groups	54.5	7	7.79		
Total	74.4	14			

4. DISCUSSION

The etiology of optic atrophy is diverse. It may result from a myriad of disease processes that include ischemia, inflammation, compression, infiltration, trauma, and hereditary which cause irreversible damage to the ganglion cells, and axons in the anterior visual pathway bow [5,13]. Optic atrophy is a known cause of both unilateral and bilateral visual impairment and blindness [10,14-16]. It may also be the presentation of life-threatening conditions such as intracranial mass

lesions (e.g. intracranial aneurysms). Optic atrophy was the most common (23.9%) ocular sign among patients with intracranial tumors in Ile-Ife, Nigeria [17]. In India, it was the presentation in 18% patients with intracranial space occupying lesions [18]. Compression of the anterior visual pathway by mass lesions may result in optic atrophy. In this study, 11.1% presented with papilloedema (evident in swollen disc) as the cause of optic atrophy. Eight (8%) cases of optic atrophy due to orbitocranial tumors were reported in a study by Oluleye, et al. [10].

In this study, the most common etiology was seen in retinitis pigmentosa (20%) and nutritional amblyopia (20%). Retinitis pigmentosa was a cause of optic atrophy in 3% of the sample population studied by Oluleye, et al. in Ibadan, Nigeria [10]. In Southern Nigeria, bilateral optic atrophy is a feature of the tropical amblyopia syndrome or tropical ataxic neuropathy (which is characterized by bilateral optic atrophy, bilateral sensorineural deafness, myelopathy, and polyneuropathy) [19,20]. Typically, these patients have a diet consisting mainly of cassava (Mannihot) products, eaten at least twice a day with very little first-class protein in the diet [19]. In this study, nine patients had presumed nutritional amblyopia syndrome, although laboratory testing of the blood thiocyanate levels was not done. Chronic cyanide intoxication from cassava products causes segmental demyelination of nerve fibers [21]. Other known toxic-nutritional causes include anti-tuberculous medications such as ethambutol and isoniazid, methanol, tobacco, amiodarone, deficiencies of Vitamin B12 or folate, lead, quinine, tamoxifen, cafergot among many others [3]. In this study, chorioretinitis accounted for 5 (11.1%) cases of non-glaucomatous optic atrophy. But in a study by Osaguona & Okeigbemen on non-glaucomatous optic atrophy in Benin City, Nigeria, chorioretinal disease was also the most common known etiology seen in 45 (24.7%) of the study population [21]. In an earlier study in India, chorioretinal diseases accounted for 9 (9%) cases of optic atrophy. Choroidoretinal diseases cause optic atrophy from damage to the retinal ganglion cells and axons [22,23].

Trauma caused 6 (13.3%) cases of optic atrophy. Trauma was also among the common known etiologies in other studies in Nigeria accounting for 1.3-15.4% [10,24]. In India, it was responsible for 7 (7%) cases of optic atrophy [23]. Optic atrophy may result either from indirect injury to the optic nerve due to transmitted shear forces to the nerve in closed head injury such as blunt trauma, or from direct injury to the optic nerve in penetrating injuries [21]. The most common form of injury to the optic nerve is by indirect injury with an incidence of 0.5-5% of all closed head injuries [25,26]. Common causes of traumatic optic neuropathy include road traffic accidents and falls; other less common causes include assaults, stab wounds, gunshots, and trivial injuries [21]. The patient with traumatic optic neuropathy commonly presents with a history of visual loss following head trauma and may have other injuries such as fracture to the base of the

skull and multiple facial fractures with associated oculomotor nerve palsies as was the case in three patients seen in this study. Optic atrophy usually results 8 weeks after injury when there is no proper management [21]. AAION was the least cause of optic atrophy 2(4.4%) in this study and it is similar to the study done by Osaguona and Okeigbemen [21] 1 (0.96%). However, the diagnosis for AAION was ophthalmoscopy-based. Further studies may include laboratory tests such as Erythrocyte sedimentation rate (ESR) and magnetic resonance imaging (MRI).

No case of optic atrophy was related with hereditary optic atrophy, which was the situation in a study by Oluleye, et al. on etiology of optic atrophy [10]. The diagnosis of hereditary optic atrophy may be made, perhaps, if patients' relatives are examined and genetic studies done in those suspected of having familial optic atrophy (bilateral, symmetric visual loss, bilateral optic atrophy and probable family history of vision loss). It is notable, however, that facilities for genetic studies are not readily available or affordable in this environment.

Similar to other studies in which the etiology of optic atrophy could not be determined in 62 (62%) [10] and 9 (69.2%) [24] cases respectively, the etiology could not also be determined in 9 (20%) of the patients in this study. However, this high percentage of undiagnosed cases may be due to the fact that there was relatively less amount of facilities. Because some of our patients are poor historians it was hard to make accurate diagnosis. According to Chi-square statistic test, prevalence of non-glaucomatous optic atrophy is dependent on its causes.

From the research, 46.7% prevalence of non-glaucomatous optic atrophy was found in male and 53.3% was found in female. It was comparable with the study done by Bajracharya, et al. in Lumbini eye institute where the prevalence of non-glaucomatous optic atrophy was 54% in male and 46% in female [27]. It is also similar to a study done in Port Harcourt where 52.5% male and 47.5% female was found. But in a study done in India, 66% were male and 34% were female. In the study done by Oluleye, et al. male:female ratio was 2:1 [15]. This research study showed that non-glaucomatous optic atrophy is not sex dependent.

The highest prevalence of non-glaucomatous optic atrophy was present in patients between 57-67 years (20%) and 67-77 years (20%),

followed by patients between 27–<37 (17.8%). It is similar to the study done in Singapore where highest incidence was in 5th decade (25%), followed by 6th decade (18.75%) and above 40 years it was (56.8%) [28].

The mean age in this study was 54.8 years (± 17.7 years SD). The mean age was 40 years (± 18.7 years SD) in a study done by Pedro-Egbe *et al.* (2011) [11].

This study was analyzed with the use of ANOVA test of significance at $P= 0.05$ level of significance, and it was concluded that prevalence of non-glaucomatous optic atrophy is not age dependent.

Finally, a study by Osaguona & Okeigbemen revealed that the highest prevalence of non-glaucomatous optic atrophy was present in eyes with visual acuity <3/60–NLP (52%), followed by eyes with visual acuity of 6/18 or better (26%) [21]. In this study, the highest prevalence was present in eyes with visual acuity 6/6–6/18 (34.6%), followed by <6/18–6/60 (24.7%). But in a study done by Pedro-Egbe, *et al.* [11] the highest prevalence was 18% in 28 eyes with 6/60 followed by 14.2% in 22 eyes with CF. This variation may be based on research design. According to Chi-square statistic test, prevalence of non-glaucomatous optic atrophy is dependent on visual acuity. The current study had some limitations. Some patients were not able to quote their actual age due to poor educational background. The result on sex may be biased as the ratio of males to females who attended the community outreach was not equal. Because of finance and time constraint, the whole communities in Ehime Mbanjo were not visited during the course of the outreach which affected the sample size. In some subjects, the optic nerve head could not be accessed for optic atrophy due to cataract even after dilation. Computerized visual field test was not performed on subjects due to risk of damage and bulkiness. Neuroimaging will be useful in further studies.

5. CONCLUSION

1. Optic atrophy is the end result of injury to the anterior visual pathway from a myriad of disease processes which can lead to irreversible blindness.
2. The total prevalence of non-glaucomatous optic atrophy in Ehime Mbanjo is 13.0%.
3. According to statistical analyses, the prevalence of non-glaucomatous optic

atrophy is dependent on its causes and visual acuity but not dependent on sex and age.

6. RECOMMENDATION

1. A patient with optic atrophy should be thoroughly evaluated as it may be a treatable condition or presentation of a life-threatening condition.
2. The level of optic nerve function should be determined by visual acuity, color vision, brightness sensitivity testing, confrontation and formal perimetry.
3. Patients' relatives should be examined, and genetic testing should be done on patients suspected of having hereditary optic neuropathy.
4. More sophisticated instruments such as visual field analyzer, fundus photography and neuroimaging should be used in further research to increase the reliability.
5. Inhabitants of Ehime Mbanjo should try their best to eat a well processed cassava product as nutritional amblyopia is of high prevalence in this study.
6. Since there is no treatment proven effective, early diagnosis and timely management of underlying cause is the key factor to prevent optic atrophy.

CONSENT AND ETHICAL APPROVAL

The study protocol was approved by the Department of Optometry Ethics Committee, Abia State University, Uturu, Nigeria. Advocacy visits were made and request letters were sent to leaders of various communities who gave their consent and ensured that adequate awareness was created for the outreach programs in Ehime Mbanjo, Imo state, Nigeria.

COMPETING INTERESTS

Authors have declared that no competing interests exist.

REFERENCES

1. Lee AG. Neuro-ophthalmic afferent system diagnoses a general ophthalmologist should (almost) never make alone. Middle East African Journal of Ophthalmology. 2009;16(1):41.
2. Ogun O, Adediran O. Non-glaucomatous optic neuropathy in Ibadan: Extrapolations to healthcare funding in Nigeria. Annals of

- Ibadan Postgraduate Medicine. 2014; 12(2):103-8.
3. Golnik K. Nonglaucomatous optic atrophy. *Neurologic Clinics*. 2010;28(3):631-40.
 4. DeWitt CA, Johnson LN, Schoenleber DB, Hainsworth DP, Madsen RW. Visual function in patients with optic nerve pallor (optic atrophy). *Journal of the National Medical Association*. 2003;95(5):394.
 5. Bowling B. *Kanski's clinical ophthalmology: A systemic approach*. 8th ed. Elsevier, editor: Elsevier; 2016.
 6. Khurana AK. *Comprehensive ophthalmology*. 5th ed. Limited NaiPs, editor. Delhi: New age international Publisher's Limited; 2012.
 7. Obuchowska I, Mariak Z. Ischemic optic neuropathy. Pathogenesis, clinical features, diagnostics and treatment. *Klinika Oczna*. 2006;108(4-6):238-42.
 8. Abdull MM, Sivasubramaniam S, Murthy GV, Gilbert C, Abubakar T, Ezelum C, et al. Causes of blindness and visual impairment in Nigeria: The Nigeria national blindness and visual impairment survey. *Investigative Ophthalmology & Visual Science*. 2009;50(9):4114-20.
 9. Olusanya B, Onoja G, Ibraheem W, Bekibele C. Profile of patients presenting at a low vision clinic in a developing country. *BMC Ophthalmology*. 2012;12(1): 31.
 10. Oluleye TS, Ajaiyeoba A, Fafowora O, Olusanya B. The aetiology of optic atrophy in Nigerians—A general hospital clinic study. *International Journal of Clinical Practice*. 2005;59(8):950-2.
 11. Pedro-Egbe CN, Cookey S, Awoyesuku EA, Ani N. Nonglaucomatous optic neuropathies in Port Harcourt. *Clinical Ophthalmology (Auckland, NZ)*. 2011;5: 1447.
 12. Ndubueze D, Igboekwe MD, Ebong E. Assessment of Groundwater Potential in Ehime Mban, Southeastern Nigeria. 2019;7.
 13. Grosvenor TP. *Primary care optometry*. 5th ed. ed. St Louis, Missouri: Butterworth-Heinemann; 2007.
 14. Adegbehingbe BO, Majengbasan TO. Ocular health status of rural dwellers in south-western Nigeria. *Australian Journal of Rural Health*. 2007;15(4):269-72.
 15. Oluleye T, Ajaiyeoba A, Akinwale M, Olusanya B. Causes of blindness in Southwestern Nigeria: A general hospital clinic study. *European Journal of Ophthalmology*. 2006;16(4):604-7.
 16. Osaguona V, Ukponmwan C, Kayoma D, Okojie O. Ocular health status of patients seen at the screening centre of the University of Benin Teaching Hospital, Benin City, Nigeria—A preliminary report. *Journal of Medicine and Biomedical Research*. 2012;11(2):44-50.
 17. Onakpoya O, Komolafe E, Akintomide F, Ajite K, Komolafe M, Adeolu A, et al. Ophthalmic manifestations in patients with intracranial tumours. *African Journal of Neurological Sciences*. 2009; 28(1).
 18. Raju K, Khader AA. Ocular manifestations of intracranial space occupying lesions—A clinical study. *Kerala J Ophthalmol*. 2009; 21:248-52.
 19. Ayanru J. The tropical amblyopia syndrome (or tropical nutritional amblyopia) in the Mid-Western State of Nigeria. *African Journal of Medicine and Medical Sciences*. 1976;5(1): 41-8.
 20. Oluwole O, Onabolu A, Link H, Rosling H. Persistence of tropical ataxic neuropathy in a Nigerian community. *Journal of Neurology, Neurosurgery & Psychiatry*. 2000;69(1):96-101.
 21. Osaguona VB, Okeigbemen VW. Nonglaucomatous optic atrophy in Benin City. *Annals of African Medicine*. 2015; 14(2):109.
 22. Chinta S, Wallang BS, Sachdeva V, Gupta A, Patil-Chhablani P, Kekunnaya R. Etiology and clinical profile of childhood optic nerve atrophy at a tertiary eye care center in South India. *Indian Journal of Ophthalmology*. 2014;62 (10):1003.
 23. Chaddah M, Khanna K, Chawla G. Optic atrophy (Review of 100 cases). *Indian Journal of Ophthalmology*. 1971;19(4): 172.
 24. Omoti A, Waziri-Erameh M. Pattern of neuro-ophthalmic disorders in a tertiary eye centre in Nigeria. *Nigerian Journal of Clinical Practice*. 2007;10(2): 147-51.
 25. Carta A, Ferrigno L, Salvo M, Bianchi-Marzoli S, Boschi A, Carta F. Visual prognosis after indirect traumatic optic neuropathy. *J Neurol Neurosurg Psychiatry*. 2003;74(2):246-8.
 26. Simon S, Torpy D, Brophy B, Blumbergs P, Selva D, Crompton JL. Neuro-ophthalmic

- manifestations and outcomes of pituitary apoplexy—a life and sight-threatening emergency. *Signs*. 2004;8(1/23).
27. Bajracharya K, Gautam P, Yadav SK, Shrestha N. Epidemiology and causes of optic atrophy in general outpatient department of Lumbini eye institute. *Journal of Universal College of Medical Sciences*. 2015;3(2):26-9.
28. Loh R. Acquired optic atrophy in Singapore: A study. *Singapore Medical Journal*. 1968;9(2):73.

© 2020 Ihesiulor et al.; This is an Open Access article distributed under the terms of the Creative Commons Attribution License (<http://creativecommons.org/licenses/by/4.0>), which permits unrestricted use, distribution, and reproduction in any medium, provided the original work is properly cited.

Peer-review history:
The peer review history for this paper can be accessed here:
<http://www.sdiarticle4.com/review-history/53868>