

Acute Retinal Necrosis Syndrome: Case Report and Literature Review

**M. Essakhi^{1*}, B. Jatic¹, I. Er-rachiq¹, A. Mchachi¹, L. Benhmidoune¹, A. Chakib¹,
R. Rachid¹ and M. Elbelhadji¹**

¹*Department of Adult Ophthalmology, Faculty of Medicine and Pharmacy, University of Hassan II Casablanca, Hospital 20 August 1953, Ibn Rochd UHC, Morocco.*

Authors' contributions

This work was carried out in collaboration among all authors. Author ME designed the study, performed the statistical analysis, wrote the protocol and wrote the first draft of the manuscript. Authors BJ and IER managed the analyses of the study. Author ME managed the literature searches. All authors read and approved the final manuscript. All authors read and approved the final manuscript.

Article Information

Editor(s):

(1) Dr. Iman Mohammed Magdy Eissa, Assistant Professor, Department of Ophthalmology, Faculty of Medicine, Cairo University, Egypt.

Reviewers:

(1) Asaad Ahmed Ghanem, Mansoura University, Egypt.
(2) Shubha Ghonsikar Jhavar, Government Medical College, Aurangabad, India.
Complete Peer review History: <http://www.sdiarticle4.com/review-history/54246>

Case Study

Received 20 November 2019
Accepted 25 January 2020
Published 31 January 2020

ABSTRACT

Acute retinal necrosis (ARN syndrome) is a rare syndrome; the germs involved belong to the herpes virus family. Complications include cystoid macular edema and retinal detachment, which is a frequent complication with a poor prognosis. We report the case of an immunocompetent patient with unilateral acute retinal necrosis due to VZV. The drop in visual acuity was brutal. Intravenous antiviral and anti-inflammatory therapy was initiated on an emergency basis, followed by oral maintenance therapy. The patient was complicated during this treatment by cystoid macular edema treated with retrobulbar steroids injections. The Knowledge of this condition, which diagnosis is essentially clinical, is necessary in order to avoid the extension of retinal necrosis and to prevent the recurrence of complications.

Keywords: Acute retinal necrosis; herpes simplex virus; varicella zoster virus; macular edema.

*Corresponding author: E-mail: essmeriem365@hotmail.fr;

1. INTRODUCTION

Acute retinal necrosis (ARN syndrome) is a rare disease first described in 1971 by Uryama [1]. On the basis of 2 nationwide UK surveys, the annual incidence of ARN is estimated to be 0.5 to 0.63 new cases per million population [2].

The Executive Committee of the American Uveitis Society defined ARN on the basis of the following clinical characteristics: (1) 1 or more foci of retinal necrosis with discrete borders located in the peripheral retina, (2) rapid progression in the absence of antiviral therapy, (3) circumferential spread, (4) evidence of occlusive vasculopathy with arterial involvement, and (5) a prominent inflammatory reaction in the vitreous and anterior chamber [2]. The infectious agents involved in this disease belong to the herpes virus family: Herpes simplex virus types 1 and 2 (HSV 1 and 2), Varicella zoster virus (VZV) and cytomegalovirus (CMV) [3]. Its positive diagnosis is based on the suggestive clinical appearance, the ocular/serum antibody ratio and the anterior chamber polymerase chain reaction (PCR) technique [4].

ARN syndrome is a diagnostic and therapeutic emergency due to its severe spontaneous evolution towards the extension of retinal necrosis and the risk of bilaterality which requires more or less prolonged prophylactic treatment [5, 6]. The prognosis depends on the extent of retinal necrosis, damage to the optic nerve and complications, mainly retinal detachment [5]. We report the case of complicated ARN syndrome during treatment with cystoid macular edema.

2. PRESENTATION OF CASE

Male, 28 years old, no specific pathological history. Who presented with redness of the eye and rapidly progressive loss of visual acuity in the right eye that occurred 5 days prior to admission.

The ophthalmological examination of the right eye shows a visual acuity quantified by counting the fingers at 2 meters, the ocular tension was normal at 15 mmHg, the examination of the anterior segment found retrocorneal pigmented precipitates and protein tyndall of the anterior chamber at 2+. The fundus revealed a vitreous tyndall 2+, a confluent foci of whitish retinal necrosis extending from the periphery to the center, arteritis and papilledema [Fig. 1]. Examination of the anterior and posterior segment of the left eye was normal with visual acuity at 10/10 P2.

Fluorescein angiography of the right eye showed delayed arterial filling, with an area of extensive peripheral retinal ischemia and arteritis. The diagnosis of acute retinal necrosis was immediately raised.

Intravenous acyclovir 10 mg/kg every 8 hours was immediately initiated and continued for two weeks followed by oral relay by Valaciclovir 1 g*3/day and abolus of corticosteroids (methylprednisolone) at 10 mg / kg / day for 3 days, was started 48 hours after the antiviral treatment, then he was transitioned to oral corticosteroids (prednisone) at a dose of 1 mg / kg / day. Topical treatment with corticosteroids and cycloplegics has been recommended.

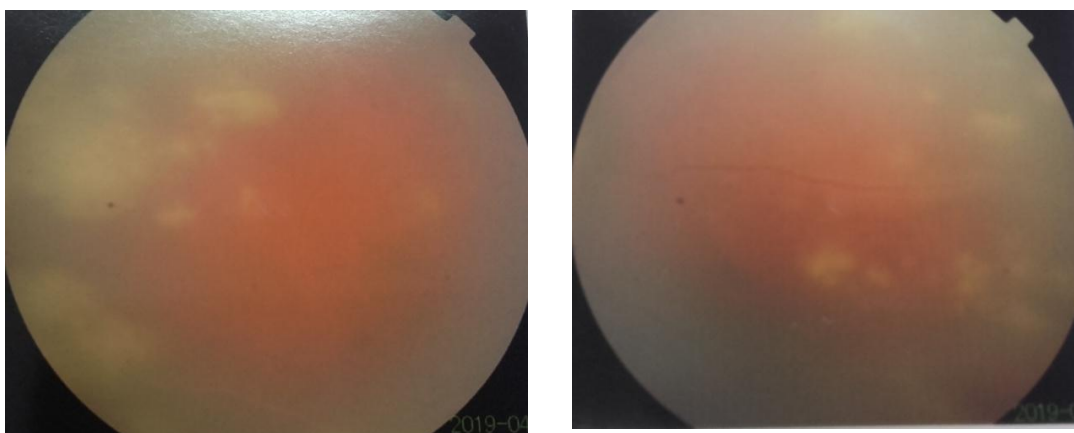


Fig. 1. Fundus image showing a vitreous tyndall effect and papilla and 360° circumferential yellowish-white retinal opacities and minimal vasculitis involving the arterioles

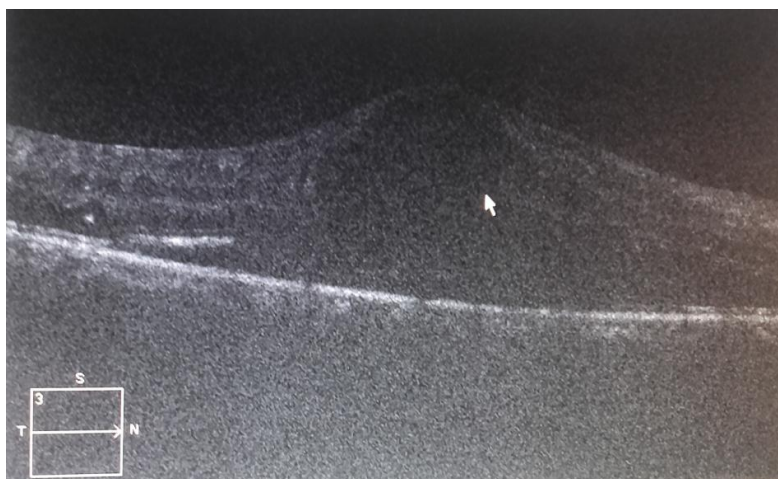

Fig. 2. Optical coherence tomography image of the right eye showing a cystoid macular edema that appeared during treatment of ARN syndrome

Biological results showed normal blood cell counts and normal serum chemistries. Erythrocyte sedimentation rate was 15 mm/h. Human immunodeficiency virus (HIV), HSV 1 and 2, VZV and CMV serologies were negative. The aqueous humor was evaluated for Herpes Simplex Virus (HSV), Varicella Zoster Virus (VZV) and Cytomegalovirus (CMV) by polymerase chain reaction (PCR). The serum VZV PCR was found to be positive while the others were negative. Testing for toxoplasmosis and syphilis were also negative. A prophylactic photocoagulation of the retinal periphery was performed after the first 15 days to prevent retinal detachment.

The evolution was marked by an improvement under treatment of visual acuity which went up to 6/10 P3 of the right eye and a disappearance of the anterior chamber tyndall and The fundus exam on the right showed near complete resolution of peripheral areas of necrosis. The examination of the left eye was normal with visual acuity at 10/10 P2.

The treatment was relayed by antiviral maintenance therapy: Valaciclovir per os 500 mg twice a day. A month later, the patient presented a decrease in visual acuity of the right eye to 2/10 P6 with a macular syndrome made of micropsia and metamorphopsia. Macular Optical Coherence Tomography revealed a cystoid macular edema [Fig. 2]. An injection of dexamethasone retrobulbar steroid, followed by an injection of triamcinolone retrobulbar steroid (Kenacort®), resulted in partial recovery of visual acuity of 4/10 P5 on the right.

3. DISCUSSION

The viral origin of ARN syndrome was not initially clearly recognized. In 1977, the viral etiology was suspected by Willerson. It was not until 1982 that the etiology of the disease was elucidated by Culbertson et al. [7], following the detection by electron microscopy of a virus of the Herpesviridae family in the retina of an enucleated eye. Varicella zoster virus (VZV) and herpes simplex virus types 1 and 2 were identified by culture [8]. Cytomegalovirus has been implicated as a pathogen in rare cases [8].

The mechanism of retinal infection is probably reactivation in the central nervous system from a viral latency focus [9,10]. Blood or contiguous spread from the anterior segment is not involved. A genetic predisposition has been reported [8]. Some studies have suggested an association of the HLA DR9 haplotype with the degree of severity of the ARN.

There are two peak frequencies for the age of ARN patients, the first between 20-30 years of age where herpes simplex virus type 2 is predominant and the second between 50-60 years of age where varicella zoster virus is common [11]. In addition, a slight male predominance (57% of cases) is found [12].

Acute retinal necrosis (ARN) is seen in immunocompetent individuals, occurring after VZV and HSV infections [13]. Despite an efficient immune system, retinal damage is sudden or rapidly progressive, which is explained by the high virulence of the HSV viruses. Cases of

immunocompromised patients presenting with ARN secondary to CMV have also been reported [13]. A history of viral infections is a risk factor for ARN syndrome [5]: chicken pox (70.6%), shingles (29.2%), ophthalmic shingles (20.7%), HSV influenza-like illness (25%), HSV encephalitis (15.4%).

The diagnosis of ARN syndrome is clinical. Patients consult mainly for decreased visual acuity, conjunctival hyperemia and myodesopsias. Standardized diagnostic criteria were proposed in 1994 by the American Uveitis Society, based entirely on clinical examination and disease progression [14]:

- Single or multiple zone(s) of retinal necrosis with sharp edges
- Necrotic foci usually located in the periphery of the retina
- Rapid progression of the disease, if anti-herpetic treatment is not started.
- Circumferential extension of retinal necrosis foci
- Presence of occlusive vasculopathies with arteriolar involvement
- Marked inflammation of the anterior chamber and the glazing
- Characteristics that may be present but not necessary for diagnosis :
 - Optic neuropathy or atrophy
 - Scleritis
 - Pain

Retinal detachment is a complication of poor visual prognosis of ARN syndrome, found in 75% of cases, occurring most frequently after the third week and in the first 5 months of the condition [15].

The analysis of the aqueous humor or vitreous by PCR (polymerase chain reaction) technique is currently the most reliable diagnostic test [8]. PCR is very sensitive (80-96%) and requires only a small amount of sample [3]. It can detect viral DNA by gene amplification [8]. The puncture should be performed under standard conditions of surgical hygiene, under topical anaesthesia in the operating room. Do not hesitate to repeat the sampling if the first result is negative [3].

The serum antibody titer has little diagnostic value. Diagnostic accuracy is increased by relating the titer of ocular antibodies to that of serum antibodies [8]. Local ocular infection has little effect on systemic antibody titers [8].

Globally, the virus primarily responsible for ARN syndrome is VZV, followed by HSV-1, HSV-2 and rarely, by CMV.

In front of an atypical clinical picture with an unfavourable evolution in spite of a well-conducted and timely treatment and negative PCR results. It is necessary to eliminate differential diagnoses. These various etiologies are represented in descending order [16]:

- Extensive Toxoplasma Retina Choroid S (62.5%).
- Syphilitic relapses (12%).
- Aspergillus Endophthalmitis (12.5%).
- Intraocular lymphomas (6.2%).
- Necrotizing retinitis of Behçet's disease (6.2%).

ARN syndrome is a therapeutic emergency due to the rapidity of its evolution and the seriousness of its complications. The objectives of treatment are to stop retinal necrosis in order to prevent complications of the disease and to prevent bilateralization.

The treatment is essentially based on the antiviral treatment with anti-inflammatory drugs and possibly antithrombotics. Acyclovir (Zovirax) by its inhibitory action on viral DNA polymerase accelerates the regression of retinitis areas and prevents damage to the adelic eye [8]. The recommended dose is 10 mg/Kg/8 hours intravenous (IV) for 3 weeks until healing of the lesions. Oral relay is undertaken with valaciclovir at 3 g/day in decreasing doses [3]. The dosage of the maintenance treatment is not well defined. It should be maintained until complete healing of the necrosis sites (corresponding to the most frequent delay of bilateralization) [8]. In case of resistance to acyclovir, foscarnet (Foscavir®) may be used. Side effects are infrequent. Monitoring of renal status (urea and creatinine) and liver enzymes is recommended during treatment [8]. An intravitreal injection of 2 mg ganciclovir (Cymévan®) is an effective option because it provides a higher intravitreal concentration of antivirals than that obtained with initial systemic antiviral therapy, essentially in immunocompromised patients [3].

The advent of new oral antiviral therapies with greater bioavailability has led to greater use of first-line oral therapy. The interest would therefore be to reduce the length of hospitalisation, the cost, and to avoid the side effects of acyclovir such as nephrotoxicity and psychiatric disorders [3].

The inflammatory part of ARN, which is partly responsible for hyalitis, vitreoretinal tractions, vasculitis and optic neuropathy, explains the need for anti-inflammatory treatment with corticosteroids with close monitoring. The recommended dose is a bolus of methylprednisolone relayed by prednisone at a dose of 1 mg/kg/day (or its equivalent) to be started 1-2 days after the start of Acyclovir treatment [8]. Antithrombotic therapy with aspirin at a dose of 500 mg/day is sufficient to combat platelet dysfunction [8]. Corticosteroids in the form of eye drops are prescribed to treat the inflammatory part of anterior uveitis in the acute phase [17].

The main complications of ARN syndrome are cataract (26%), optic atrophy (23.9%), retinal detachment (17.4%), and also cystoid macular edema [11]. Prophylactic treatment by photocoagulation of the retinal periphery should be carried out as quickly as possible (the first two weeks) in ARN syndrome complicated by retinal detachment. Lau et al. [15] report a post-laser detachment rate of 35.3% versus 80% without a laser, which explains the significantly reduced incidence of retinal detachment.

Approximately 1/3 of cases with ARN syndrome can bilaterally affect the eye if left untreated [12]. The time to bilateralisation is highly variable, occurring in 57% in the first month and in 79% in the first four months after first eye involvement [18]. The recurrences of ARN syndrome in the same eye are exceptional [19].

For Matsu O et al. [20], the prognosis is all the more gloomy as:

- Retinitis evolves rapidly towards the posterior pole, that vasculitis is extensive, that vitreoretinal tractions are important.
- Waves a and b of the electroretinogram are reduced from the outset.
- The level of immune complexes circulating in the blood is high.
- The patient is young.

The initial extent of necrosis would be of no prognostic value. Early medical treatment and preventive photocoagulation improve final visual acuity [21]. VZV appears to be more aggressive (extension of necrosis) than other viruses and to provide resistance to acyclovir while HSV appears to have a higher risk of recurrences [11]. Furthermore, there is no correlation between the

pathogen and the incidence of retinal detachment [11,15].

4. CONCLUSION

Although it is an uncommon disease, Acute retinal necrosis should be associated with substantial ocular morbidity. The functional prognosis of ARN syndrome remains poor due to retinal complications, the most common of which is retinal detachment. ARN syndrome be discussed in principle in front of any anterior uveitis associated with areas of retinal necrosis. Diagnostic confirmation is obtained by puncturing the anterior chamber and the vitreous with the polymerase chain reaction study. Early management with intravenous antiviral therapy, followed by prophylactic treatment, appears to limit necrosis and improve prognosis. Antiviral treatment should be combined with anti-inflammatory and anticoagulant therapy. The benefit of early vitrectomy and prophylactic laser for retinal detachment is not yet proven.

CONSENT

As per international standard or university standard, patient's consent has been collected and preserved by the authors.

ETHICAL APPROVAL

As per international standard, written ethical approval has been collected and preserved by the author(s).

COMPETING INTERESTS

Authors have declared that no competing interests exist.

REFERENCES

1. Urayama A, Yamada N, Sasaki T, et al. Unilateral acute uveitis with retinal periarthritis and detachment. *RinshoGanka* 1971;25:607-19.
2. Scott D. Schoenberger, MD, Stephen J. Kim, MD, Jennifer E. Thorne, MD, PhD et al. Diagnosis and treatment of acute retinal necrosis. A Report by the American Academy of Ophthalmology. *Ophthalmic Technology Assessment*. 2016;11:007.
3. Izambarta C, Zura C, Fiandrino P, et al. Management of acute retinal necrosis syndrome complicated by cystoid macular

- edema. French Journal of Ophthalmology 2009;32.60:e1- 60.
4. Snyers B. Herpetic retinal necrosis. Bull SocBelgeOphtalmol. 2000;277:27-33.
 5. Alami F, Nafizy I, Sufi G, and all. Acute retinal necrosis: About one case. Images in Ophthalmology. 2013;2:1.
 6. Dascalu AM, Stana D, Popa-Cherecheanu A, Popa-Cherecheanu M, Serban D. Fulminant bilateral acute retinal necrosis after chickenpox—a case report. Romanian journal of ophthalmology. 2016;60(3):184.
 7. Culbertson W, Blumenkranz WMS, Haines H, et al. The acute retinal necrosis syndrome, part 2: histopathology and etiology. Ophthalmology. 1982;89:1317-1325.
 8. Snyers B. Herpetic retinal necrosis. Bull. Soc. Belge Ophtalmol. 2000;277:27-33.
 9. Matsubara S, Atherton SS. Spread of HSV-1 to the suprachiasmatic nuclei and retina in T cell depleted BALB/c mice. J Neuroimmunol. 1997;80(1-2):165-71.
 10. Menendez CM, Carr DJ. Defining nervous system susceptibility during acute and latent herpes simplex virus-1 infection. Journal of Neuroimmunology. 2017;308: 43-49.
 11. Tran TH, Bodaghi B, Rozenberg F, and all. Diagnostic and therapeutic management of herpetic necrotizing retinitis. J Fr Ophtalmol. 2004;27:223-36.
 12. Labetoulle M. Acute retinal necrosis syndrome. J Fr Ophtalmol. 1995;18(12): 799-818.
 13. Archana Vasudevan, Christian Rojas-Moreno, Tushar Tarun. Acute retinal necrosis secondary to Varicella Zoster Virus. ID Cases 18. 2019;e00585.
 14. Holland GN. Standard diagnostic criteria for the acute retinal necrosis syndrome. Executive Committee of the American Uveitis Society. Am J Ophthalmol. 1994; 117(5):663-7.
 15. Lau CH, Missotten T, Salzmann J, and all. Acute retinal necrosis features, management, and outcomes. Ophthalmology. 2007;114:756—62
 16. Balansard B, Bodaghi B, Cassoux N, et al. Necrotising retinopathies simulating acute retinal necrosis syndrome. The British journal of ophthalmology. 2005;89(1):96-101.
 17. Duker JS, Blumenkranz MS. Diagnosis and management of the acute retinal necrosis (ARN) syndrome. Surv Ophthalmol. 1991;35(5):327-43.
 18. Saari KM, Boke W, Manthey KF, and all. Bilateral acute retinal necrosis. Am J Ophthalmol. 1982;93(4):403-11.
 19. Altamirano D, Rochat C, Claeys M, et al. Acute retinal necrosis: A result of immune dysfunction? Report of a case with subacute evolution and relapses in a patient with impaired cellular immunity. Ophthalmologica. 1994;208(1):49-53.
 20. Matsuo T, Morimoto K, Matsuo N. Factors associated with poor visual outcome in acute retinal necrosis. The British journal of ophthalmology. 1991;75(8):450- 4.
 21. Ichikawa T, Sakai J, Yamauchi Y, et al. A study of 44 patients with Kirisawa type uveitis. Nippon Ganka Gakkai Zasshi. 1997;101(3):243-7.

© 2020 Essakhi et al.; This is an Open Access article distributed under the terms of the Creative Commons Attribution License (<http://creativecommons.org/licenses/by/4.0>), which permits unrestricted use, distribution, and reproduction in any medium, provided the original work is properly cited.

Peer-review history:

The peer review history for this paper can be accessed here:
<http://www.sdiarticle4.com/review-history/54246>